



Growth as a corrective force in the early treatment of progressive infantile scoliosis

M. H. Mehta

From the Royal
National
Orthopaedic
Hospital Trust,
Stanmore, England

This prospective study of 136 children with progressive infantile scoliosis treated under the age of four years, and followed up for nine years, shows that the scoliosis can be reversed by harnessing the vigorous growth of the infant to early treatment by serial corrective plaster jackets.

In 94 children (group 1), who were referred and treated in the early stages of progression, at a mean age of one year seven months (6 to 48 months) and with a mean Cobb angle of 32° (11° to 65°), the scoliosis resolved by a mean age of three years and six months. They needed no further treatment and went on to lead a normal life. At the last follow-up, their mean age was 11 years and two months (1 year 10 months to 25 years 2 months), 23 (24.5%) were at Risser stages 4 and 5 and 13 girls were post-menarchal.

In 42 children (group 2), who were referred late at a mean age of two years and six months (11 to 48 months) and with a mean Cobb angle of 52° (23° to 92°), treatment could only reduce but not reverse the deformity. At the last follow-up, at a mean age of ten years and four months (1 year 9 months to 22 years 1 month), eight children (19%) were at Risser stages 4 and 5 and five girls were post-menarchal. Fifteen children (35.7%) had undergone spinal fusion, as may all the rest eventually.

Scoliosis increases with growth and the rate of deterioration keeps pace with the rate of growth of the child, being greatest in infancy and adolescence. Studies of the natural history of untreated or late treated progressive infantile scoliosis have shown that in some infants the deformity can increase rapidly to a severe, disfiguring and unmanageable degree by the age of two or three years, with further relentless progression to skeletal maturity.¹⁻⁴ Severe scoliosis arising in infancy produces cosmetic disfigurement and, by its constrictive effect on the lungs, restricts the multiplication of pulmonary alveoli, which begins at birth and increases to almost the adult number of 300 million by the age of eight years.⁵ Social and psychological dysfunction may stem from the distress and embarrassment caused by severe deformity, and major cardiopulmonary damage may be manifest in adult life.⁶ Leatherman and Dickson⁷ emphasised that severe scoliosis in infancy caused by complex congenital anomalies of the vertebrae and rib cage also carries a similar cardiorespiratory hazard.

Growth has therefore come to be regarded with some apprehension as an adversely influencing factor in the evolution of a progressive scoliosis when the deformity is allowed to

grow unchecked in its early stages and treatment is given late. Growth, however, is not intrinsically an adverse agent. On the contrary, it is against a background of rapid growth in infancy that a spontaneously resolving infantile scoliosis corrects into a straight spine.

A retrospective study by the author⁸ of the complete clinical records, including radiographs taken before the age of two years, of 361 patients with infantile scoliosis, concluded in 1968, led to the development of a method of early diagnosis between the resolving and progressive forms of infantile scoliosis. The method⁹ measures, on a supine radiograph, the angles formed by the apical vertebra of the scoliosis and its corresponding concave and convex side ribs; the rib vertebral angle of difference (RVAD) between them is recorded. In resolving curves, the RVAD on the first radiograph was < 20° and it was decreased on a subsequent radiograph taken two or three months later. In progressive scoliosis, however, the initial RVAD was > 20° and on a subsequent radiograph it had either increased or remained unchanged from the previous reading. This pattern was noted in 83% of the children with the resolving and the progressive forms of infantile scoliosis. However, 17% of the cases

■ M. H. Mehta, FRCS,
Consultant Orthopaedic
Surgeon, Emeritus
ARISE - The Scoliosis
Research Trust
Graham Hill Building, Royal
National Orthopaedic
Hospital, Stanmore HA7 4LP,
UK.

Correspondence should be
sent to Dr M. H. Mehta;
e-mail:
minhmehta@aol.com

©2005 British Editorial
Society of Bone and
Joint Surgery
doi:10.1302/0301-620X.87B9.
16124 \$2.00

J Bone Joint Surg [Br]
2005;87-B:1237-47.
Received 2 November 2004;
Accepted after revision
14 February 2005

did not conform to the general pattern, with resolving curves showing RVADs of $> 20^\circ$ and progressive curves showing small RVADs $< 20^\circ$.

The clinical part of that study,⁸ based on examination of 138 of the patients, had suggested that very early treatment by serial plaster correction may lead to complete resolution of progressive infantile scoliosis. In 1979, the pooled results of 21 such children treated by this means were reported by Mehta and Morel.¹⁰ They concluded that the duration of treatment was considerably shortened if it was started at an earlier age. The mean age of their patients when treatment commenced was 3.1 years, which they regarded as rather late.

This paper is based on the hypothesis that although progressive infantile scoliosis is incapable of spontaneous resolution, it may, in its early stages possess a hidden potential for recovery. With a little help from early and appropriate treatment, the vigorous growth of infancy can straighten progressive curves which would otherwise develop into severe deformities. Resolution of a progressive scoliosis by treatment or, at worst, the prevention of a severe deformity in infancy, carries the added benefit of averting psychological dysfunction and cardiopulmonary problems in later life.

The influence of growth on the size and shape of an organism is discussed and a method of treatment based on the principle of harnessing the child's own growth as a corrective force is described. The results of a prospective study are assessed.

Growth and shape. The fastest rate of growth in man is in the first year of life. A baby with a mean length at birth of 50 cm grows by 20 to 25 cm, almost twice the mean annual gain in height of 12 to 14 cm seen at the peak of the adolescent growth spurt. In the second year growth is not quite as rapid with a gain in height of 12 to 13 cm, matching the peak at adolescence. Thereafter, the speed of growth decelerates to a steady annual gain in height of 5 to 6 cm between the ages of four and ten years.¹⁰

The distinctive and recognisable shape or form of an organism is created by the regulated growth, actual and relative, of its constituent parts. Shape may be regarded as a consequence of growth, the rate of which varies in different directions.¹¹ The shape of an organ or a part will in turn determine the direction of its further growth. As long as the direction remains constant, growth will simply perpetuate and enlarge the existing shape. Unhindered, a sphere will continue to grow spherically, a curved spine more curved. However, if the direction is altered by the continuous application of an external force, especially during a period of rapid growth, the shape of an organism can be changed. A well-known example is the permanent deformation of normal feet of baby girls by the former Chinese practice of foot-binding from birth. Another is the gradual reshaping by wooden boards of the skull bones of male and female babies of high ranking families of the southern Northwest Coast tribes of American Indians, to obtain a pointed head aesthetically admired by that culture and signifying high

social status.^{12,13} These examples suggest that by applying a constant external corrective force over a period of time it should be possible to make the scoliotic spine grow from a deformed into a normal shape, and that the earlier the treatment is begun, the greater will be the chance of success.

Patients and Methods

This prospective study of 136 children with progressive infantile scoliosis up to four years of age, treated between 1975 and 2000, was not a controlled trial since the ethics of withholding treatment are questionable when the serious consequences of no treatment or late treatment are well known.¹⁴ In place of a control group, and to demonstrate that the children had the progressive and not the spontaneously resolving form of infantile scoliosis, they were compared with 42 children with spontaneously resolving infantile scoliosis, who were also seen in the clinic and had neither needed nor received treatment (group 3; see Table V).

There were 72 boys and 64 girls (male-to-female ratio 1.1:1) with 87 left convex and 49 right convex curves (left to right ratio 1.8:1). There were 63 single, 54 double and 19 triple curves. Of these children, 129 (95%), were tertiary referrals, of whom 71 (55%) had been referred by orthopaedic spinal surgeons, 34 (26.4%) by orthopaedic surgeons and 24 (18.6%) by paediatricians. Only seven (5%) had been sent by family physicians.

The mean age at detection of the scoliosis was nine months (birth to 46 months), at referral for treatment one year and ten months (6 to 48 months) and at the last follow-up ten years and ten months (1 year 9 months to 25 years 2 months). Only four children had received treatment before referral, although many had been monitored and radiographs taken periodically.

The scoliosis was detected by the parents in 103 (76%) cases and in 33 (24%) by health-visitors, doctors or incidentally seen on a radiograph of the chest or abdomen. It was seen or felt as a slight bulge on one side of the back while bathing or winding the baby after a feed in 72 children (53%), as a C curve of the body or spine in 46 (33.8%), by a constant leaning to one side when sitting propped up in nine (6.6%) and from radiographs in a further nine (6.6%).

Children with progressive infantile scoliosis are not a homogenous group. They differ from one another in physical and mental development, in the presence or absence of other associated features and accordingly, in the rate and severity of the progression of the scoliosis which is their common feature.

Of the 136 children, 100 appeared otherwise to be normal. Their scoliosis may, by convention, be described as 'idiopathic'. However, on closer examination they were identifiable as two distinct phenotypes, possessing different physical characteristics and patterns of progression of the scoliosis.

1) Sturdy phenotype. There were 35 children in this group. They were well built, with good muscle tone. Only a few

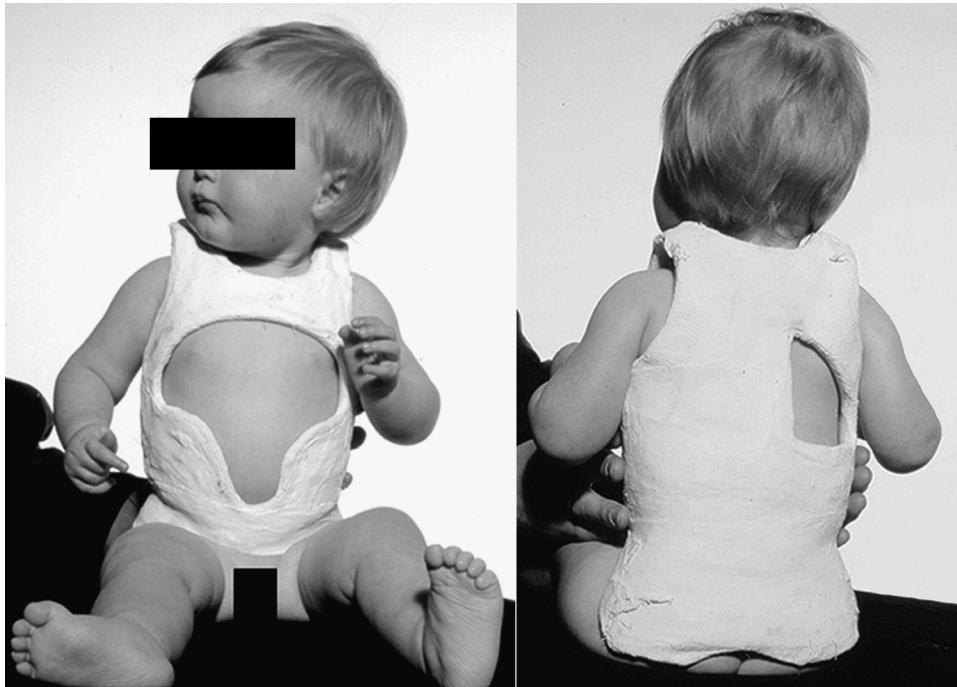

Fig. 1

Photographs of a 13-month-old girl with a left thoracic scoliosis of 45° in her first plaster-of-Paris jacket. The scoliosis resolved at the age of 29 months. She is now 15 years old, post-menarchal and her spine remains straight.

showed slight joint laxity. Their scoliosis was flexible and progressed at a steady benign pace.⁴

2) Slender phenotype. This group consisted of 65 children. They were slim and slightly built. They had reduced muscle bulk and hypotonia, joint laxity, fine skin, faint palmar lines, and sometimes, herniae and/or a strabismus. In contrast with the hypotonia and joint laxity, their scoliosis was often, but not always, stiff. It tended to progress rapidly to severe deformity but respond slowly to corrective treatment.

The remaining 36 children displayed a number of associated anomalous features, subtle or obvious, indicative of inborn constitutional disorders. Accordingly, they were grouped as 'syndromic'. After further investigation, including genetic testing, they could be separated further into two groups:

1) Named syndromes. There were 16 children in this group. Syndromes included Asperger's, Beal's, Coffin Lowry, Crouzon, atypical Retts, Larsen's, pseudocata eye secondary to 47XX+marker, lateral gaze palsy, and the Prader Willi in four children. There was one case each of congenital hemiparesis and congenital muscular dystrophy, and two of cerebral palsy. Their scoliosis and that of the next group, tended to increase even more rapidly than that in the slender phenotype.

2) Unnamed syndromes. There were 20 children in this group. All investigations failed to yield a diagnostic label. Fourteen were mentally retarded, 11 were dysmorphic, and eight had other anomalies including bilateral congenital

dysplasia of the hip, complex cardiac anomalies, pulmonary stenosis, a patent ductus arteriosus, hydrocephalus, cerebral atrophy and undiagnosed neuropathy. One child had bilateral diaphragmatic herniae with lymphangioma and laryngeal stricture. Mental retardation in children with progressive infantile scoliosis is not uncommon.¹⁴⁻¹⁶

These four clinical subgroups can be recognised at an early age and often at the first examination. The children, ranging from the sturdy phenotype to the dysmorphic with unnamed syndromes, portray, by the escalating speed and severity of progression of their scoliosis, a spectrum of increasing phenotypic vulnerability to deformity with a decreasing potential for recovery with treatment. However, all children in these four phenotypic sub-groups were treated by the same method.

The method of treatment. The scoliosis is managed in successive stages, each corrected position being held by a carefully applied and moulded plaster-of-Paris jacket. Each jacket is worn for eight to 16 weeks to allow the spine sufficient time to grow into a progressively improved direction and shape.

In very young children anaesthesia is used to avoid alarm or distress. With the child on a Cotrel frame, the scoliosis is gently corrected by traction, derotation and lateral pressure and the new position held by an unpadded modified elongation, demotation, flexion (EDF) plaster-of-Paris jacket applied over two layers of stockinet, as described by Cotrel and Morel.¹⁷ The plaster is moulded over the rib hump to flatten it. A large chest window and another window at the

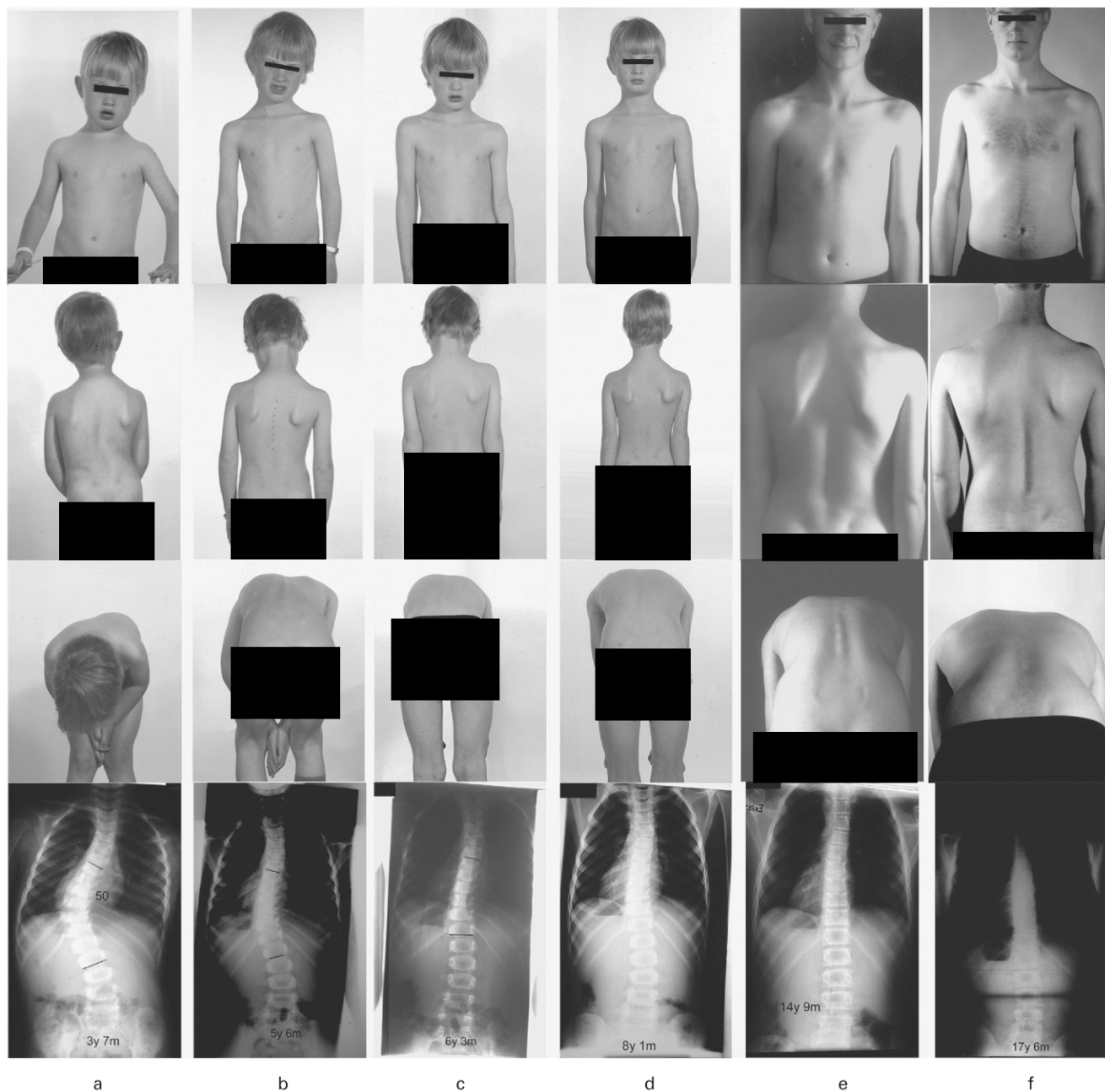


Fig. 2

Photographs and radiographs of a boy in group 1, from referral for treatment to follow-up at skeletal maturity. Figure 2a – At treatment, aged 3 years 7 months, with a left thoracic scoliosis of 50° , RVAD at T10 of 24° and in phase 2. There is a large rib hump. Scoliosis was detected at 15 months by his mother. Figure 2b – Curve corrected to 20° , RVAD 1° and in phase 1 by the age of 5 years 6 months. An underarm removable brace was prescribed. Three months later the curve had regressed to 13° and the brace was discarded. Figure 2c – At the age of 6 years 3 months, there is gradual spontaneous resolution of the residual curve and rib hump. Figure 2d – At the age of 8 years 1 month, there is further spontaneous straightening of the spine with restoration of the normal body shape. Figure 2e – A fully resolved spine. Figure 2f – At the age of 17 years 6 months and Risser stage 4. He is now aged 24 years.

back over the concavity of the curve are cut to allow good expansion of the rib cage. The outer layer of the stockinet is removed and the inner layer next to the skin is folded over the cut margins (Fig. 1). The child is allowed home the same or the following day. Normal activity is encouraged. Infants in plaster jackets soon learn to crawl, walk and even climb stairs without apparent difficulty.

The jackets are changed at intervals of eight to ten weeks for children under the age of two years who fast outgrow them and after 12 to 16 weeks in older children. The improved shape of the spine is assessed clinically and from anteroposterior radiographs taken out of the plaster jacket, but not at every change. When the radiographs show restoration of the symmetry of the rib cage, derotation of the

apical vertebra and a complete or almost complete correction of the curve itself, the jackets are relinquished. The newly-straight spine must now be stabilised in its corrected shape by a removable underarm brace, worn for a few hours each day. Good compliance with wearing of the brace is essential in order to avoid relapse and for growth to complete the resolution of any small residual curve. It also allows cortical recognition and imprinting of the midline position of the spine. If after six months the spine remains corrected, the brace is gradually discarded and treatment may cease. The child returns to living a normal life, but is followed up initially at intervals of six months and then annually until skeletal maturity.

Statistical analysis. For comparison of the means between two independent patient groups, Student's two-sample *t*-test was used. For evaluating mean changes within a group, Student's paired *t*-test was used. For the comparison of proportions between two independent groups, the chi-squared test was used and within a patient group McNemar's paired chi-squared test.

Results

Although all 136 children were treated in the same way within two to three weeks of their referral, the results were not uniform. In 94 children the scoliosis resolved (group 1). In 42 it was only corrected partially (group 2). All four phenotypic categories were represented in each group.

In group 1, there were 29 children of the sturdy phenotype, 44 of the slender phenotype, 12 with named syndromes and nine with unnamed syndromes. The male-to-female ratio was 1.2:1, and the left to right convexity ratio 2.2:1. The mean measurement of left convex curves was 33° (11° to 61°) in boys and 32° (16° to 65°) in girls. The mean measurement of right convex curves was 28° (15° to 52°) in boys and 35° (20° to 47°) in girls. The scoliosis had resolved at a mean age of 3.5 years (13 months to 9 years 8 months), with restoration of the normal body shape and spinal movements. The children needed no further treatment and went on to lead a normal life, but were followed up annually. At the last follow-up the scoliosis remained fully corrected in all but two children. Both were girls of slender phenotype, with right thoracolumbar curves detected at five and ten months and treated at 17 and 20 months, respectively. Each child's mother had adolescent idiopathic scoliosis. The first child had a T5-L1 curve of 27° and 15° of rotation, with a RVAD of 16° which, in phase 1, resolved at the age of two years seven months. She did not follow the regime of wearing a brace subsequently and her curve measured 57° at adolescence. Phase 1 indicates an early stage of progression when the shadows of the head of the rib on the convex side and of the apical vertebral body are clearly separate. The next stage in the progression of an early scoliosis, phase 2, is reached when the shadow of the head of the apical rib on the convex side overlaps the upper corner of the corresponding vertebral body.⁹ In none of the 42 children in the control group with spontaneously resolving

Table 1. Mean delay and age in months (SD; range) between detection and referral for treatment in groups 1 and 2

Stage	Group 1 (n = 94)	Group 2 (n = 42)
At detection	7 (7.1; birth to 42)	12 (11.7; birth to 46)
At referral for treatment	19 (9.7; 6 to 48)	30 (11.3; 11 to 48)
Delay	12 (8.0; 1 to 36)	18 (10.0; 2 to 43)

scoliosis (group 3) was the rib head in phase 2. The second child had a curve at T8-L2 measuring 39° with 30° of rotation and 30° of RVAD in phase 2. The curve had resolved at the age of three years, but apical vertebral rotation of 10° persisted. Her spine remained straight until the age of ten years when she grew 9 cm in eight months and, because of persistent rotation, the scoliosis recurred. Both girls have had a spinal fusion, are post-menarchal, and skeletally mature at Risser stage 5.¹⁸

The menarche had been reached in 13 of the 41 girls (32%) between 11 and 14 years of age. Twelve children were skeletally mature at Risser stage 5,¹⁷ and 11 were approaching maturity at Risser stage 4. Figure 2 illustrates the clinical and radiological appearance from treatment to resolution with follow-up to skeletal maturity in a boy of group 1.

In group 2 there were six children of the sturdy phenotype, 21 of the slender phenotype, four with named syndromes and 11 with unnamed syndromes. The male-to-female ratio was 1:1.2 and the left:right convexity ratio 1.1:1. Left convex curves had a mean measurement of 50° (30° to 80°) in boys and 59° (36° to 92°) in girls. The mean measurement of right convex curves was 50° (34° to 77°) in boys and 48° (28° to 50°) in girls. These children, whose scoliosis and rib hump were only partially corrected by treatment, remain under review. They are treated periodically by a brace or a plaster-of-Paris jacket to control progression during the years of growth. With the inevitable deterioration at adolescence all may eventually require corrective surgical stabilisation by instrumented spinal fusion. At the last follow-up, five of the 23 girls (22%) had reached the menarche at between 11 and 12 years. Five children were skeletally mature at Risser stage 5 and three were at Risser stage 4. Fifteen children had undergone two-stage anterior and posterior spinal fusion at a mean age of 12 years three months (7 years 7 months to 16 years 3 months), for curves averaging 64° (34° to 103°) with rotation of 34° (30° to 45°).

The reasons for the striking difference in the outcome of treatment in groups 1 and 2, analysed in Tables I to V, hinged on two interacting factors, namely the delay between the detection of the scoliosis and referral for treatment, and the consequence of that delay on the age of the child and the magnitude of the scoliosis at the beginning of treatment.

Table I shows the large delays between detection of the scoliosis and referral for treatment in both groups. This is

Table II. Mean (SD; range) age (mths) and radiological measurements (°) at referral for treatment in groups 1 and 2

Group	Age (mths; SD; range)	Cobb angle (°; SD; range)	Rotation (°; SD; range)	RVAD* (°; SD; range)	Phase	
					1	2
1	19 (9.7; 6 to 48)	32 (11.5; 11 to 65)	17 (9.2; 0 to 35)	28 (13.5; 0 to 70)	57	37
2	30 (11.3; 11 to 48)	52 (14.6; 23 to 92)	28 (11.5; 0 to 45)	39 (15.5; 4 to 80)	9	33

* RVAD, rib vertebra angle of difference

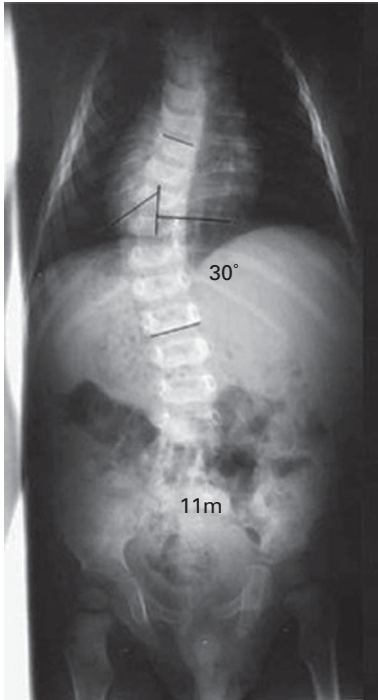


Fig. 3a

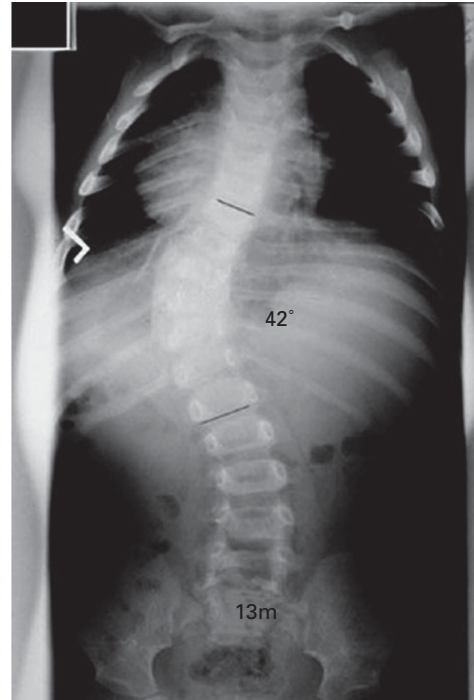


Fig. 3b

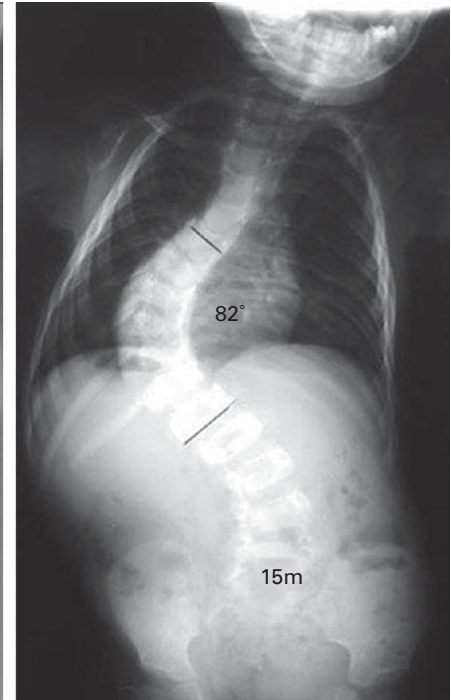


Fig. 3c

Radiographs of a boy in group 2 in whom scoliosis had been detected at eight months. Figure 3a – First pre-referral supine view at 11 months showing a curvature of 30°. Figure 3b – Second pre-referral standing view at 13 months, with the curve measuring 42° and compensatory curves above and below. Figure 3c – Standing view at referral for treatment at the age of 15 months with the curve measuring 82°. Corrective plaster-of-Paris treatment reduced but could not reverse the scoliosis. He had a posterior spinal fusion at 16 years with the curve measuring 54°. He is now aged 25 years.

significantly larger in group 2 ($p < 0.001$), being 2.8 to 9.8 months greater (95% confidence). Children in group 2 were further disadvantaged by being significantly older at detection ($p = 0.002$) and at referral ($p < 0.001$), being seven to 15 months older (95% confidence) than those in group 1. The proportion of children treated before or after the age of two years differed. In group 1, 72 (77%) children were treated by the age of two years and the remaining 22 (23%) after this age. In group 2, only 15 (35%) children were treated in the first two years of rapid growth and 27 (65%) after the age of two years during the relatively slow rate of growth in the third and fourth years.

Table II shows the consequence of the respective delays in referral of groups 1 and 2 on the age and the size of the scoliosis at the beginning of treatment. All variables were significantly larger in group 2 ($p < 0.001$). In this group, 79% of the children had progressed to a more advanced

stage, phase 2 of the rib-vertebral relationship,⁹ compared with 39% of the children in group 1. Figure 3 shows the very rapid rate of progression between the age of 11 and 15 months in a boy in group 2 whose scoliosis had been detected by his mother at the age of eight months. He was referred for treatment at the age of 15 months. Had he been referred sooner his scoliosis might have been reversed by treatment.

Table III addresses doubts as to whether the scoliosis in group 1 was truly progressive by comparing the pre-referral radiographs of 49 of the 94 children, obtained from referring hospitals, with those taken when initially seen for treatment (group 1A). It shows evidence of significant progression ($p < 0.005$) and a significant transition from phase 1 to phase 2 ($p < 0.005$) during a mean interval of seven months between the two radiographs. As attempts to obtain pre-referral radiographs of the remaining 45 chil-

Table III. Radiological evidence (mean; SD; range) of progression in 49 of the 94 patients of group 1 (group 1A; see text for explanation)

Stage	Age (mths; SD; range)	Cobb angle (°; SD; range)	Rotation (°; SD; range)	RVAD* (°; SD; range)	Phase	
					1	2
Pre-referral	11 (7.8; 1 to 40)	22 (8.7; 7 to 50)	9 (5.5; 0 to 20)	22 (11.4; 0 to 62)	42	7
At referral for treatment	18 (9.3; 7 to 48)	31 (11.1; 13 to 61)	16 (8; 5 to 30)	27 (13; 0 to 60)	31	18
p value between pre-referral and referral for treatment	< 0.001	< 0.001	< 0.001	0.005	< 0.005	

* RVAD, rib vertebra angle of difference

Table IV. Similar radiological measurements (mean; SD; range) at referral for treatment between groups 1A and 1B (see text for explanation)

Group	Age (mths; SD; range)	Cobb angle (°; SD; range)	Rotation (°; SD; range)	RVAD* (°; SD; range)	Phase	
					1	2
1A (n = 49)	18 (9.3; 7 to 48)	31 (11.1; 13 to 61)	16 (8; 5 to 30)	27 (13; 0 to 60)	31	18
1B (n = 45)	20 (10.2; 6 to 48)	33 (11.8; 11 to 65)	19 (10.2; 0 to 35)	29 (14.1; 5 to 70)	26	19
p value of difference between groups	0.32	0.24	0.11	0.6	> 0.5	

* RVAD, rib vertebra angle of difference

Table V. Mean age (mths), radiological measurements (°) and phase (number) at comparable stages in a spontaneously resolving scoliosis (group 3, n = 42) and in progressive infantile scoliosis (groups 1 and 2) (SD are given in parentheses)

Stage at	Group 3 (spontaneously resolving)						Group 1						Group 2									
	N*	Age	Cobb angle	Rotation	RVAD†	Phase		N	Age	Cobb angle	Rotation	RVAD	Phase		N	Age	Cobb angle	Rotation	RVAD	Phase		
						1	2						1	2						1	2	
Detection	42	3 (2.8)	-	-	-	-	-	94	7 (7.1)	-	-	-	-	-	42	12 (11.7)	-	-	-	-	-	-
Pre-referral	6	4 (1.6)	17 (4.9)	5 (3.3)	10 (10.1)	6	0	49	11 (7.8)	22 (8.7)	9 (5.5)	22 (11.4)	42	7	25	16 (9.8)	31 (14.4)	13 (8.8)	27 (13.7)	20	5	
Referral for treatment	42	7 (4.5)	12 (6.4)	2 (2.6)	7 (6.8)	42	0	94	19 (9.7)	32 (11.5)	17 (9.2)	28 (13.5)	57	37	42	30 (11.3)	52 (14.6)	28 (11.5)	39 (15.5)	9	33	
Resolution	42	15 (7.5)	0 (3.5)	0 (1.7)	0 (2.1)	42	0	94	42 (23.1)	6 (6.9)	4 (4.1)	8 (9)	94	0	0	-	-	-	-	-	-	
Last follow-up	42	38 (34.3)	0 (1.4)	0 (0.4)	0 (0.2)	42	0	93	134 (58.8)	4 (8.5)	2 (5.2)	2 (5.1)	91	2	42	124 (63.8)	46 (21.3)	29 (14)	32 (20)	12	30	

* N, number

† RVAD, rib vertebra angle of difference

dren (group 1B) were unsuccessful, the radiographs of groups 1A and 1B taken when seen for treatment were compared in Table IV to ascertain if they were different. No statistical evidence of difference was found in all variables ($p > 0.1$) or for phase ($p > 0.5$). Some of the variables in group 1B were, if anything, slightly larger. Tables III and IV show that the scoliosis of the 94 children of group 1, treated at an earlier age and stage of progression than the 42 children of group 2, was indeed progressive.

Table V compares the age and radiological measurements from detection to the last follow-up of the children with progressive scoliosis in groups 1 and 2, with a control group of 42 children with spontaneously resolving scoliosis who needed no treatment (group 3). The significant differences between the resolving and the two progressive groups, especially the earlier treated group 1, show that all the 136 children in this study had progressive scoliosis. The differences between group 1 and group 3 were as follows:

1) In group 1, significant progression of the curve had occurred ($p < 0.005$) between radiographs taken before and at referral (Table III). Group 3 showed no evidence of progression ($p > 0.1$) during this period. If anything, they had regressed.

2) At referral, the age and all radiological variables were significantly greater ($p < 0.001$) in group 1 than in group 3; Children in group 1 were nine to 15 months older (95% confidence).

3) Between referral and resolution, group 3 showed significant spontaneous regression in all variables ($p < 0.001$) over a period of eight months (SD 7.4). Group 1 showed significant regression during treatment in all variables ($p < 0.001$) over a period of 23 months (SD 16.9).

4) At resolution, children in group 1 were between 24 and 34 months older (95% confidence) than those in group 3.

5) In the period between resolution and the last follow-up both groups stayed resolved. None of the variables in group 3 showed any significant change but in group 1 all showed a further slight improvement after resolution, apart from phase in the two patients who had surgery.

6) At the last follow-up, group 1 had resolved to values similar to those of group 3 and there was no significant difference between them in RVAD and phase ($p = 0.15$ and 0.595 , respectively).

7) Unlike in group 1, all children in group 3 were in phase 1 at all stages.

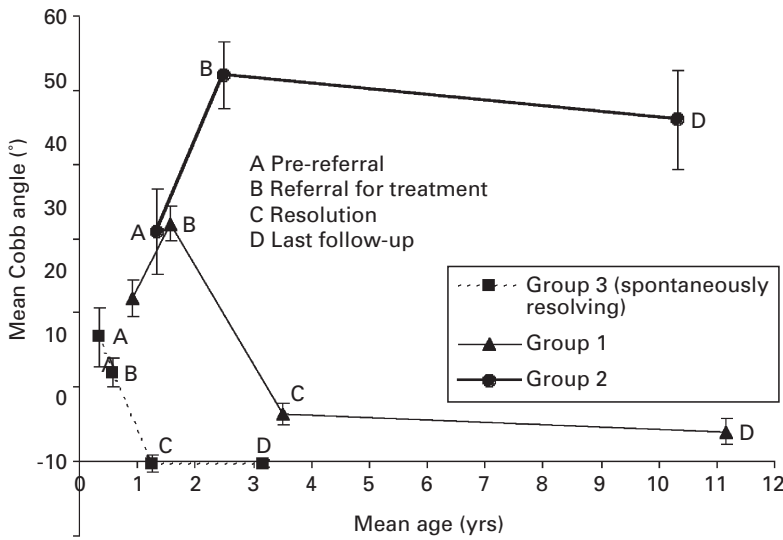


Fig. 4

Graph showing the age and Cobb angle at different stages in spontaneously resolving scoliosis and progressive scoliosis (groups 1 and 2). Note that between points A and B, the downward slope of regression in resolving scoliosis and the upward slope of progression in groups 1 and 2. Error bars are 95% confidence intervals.

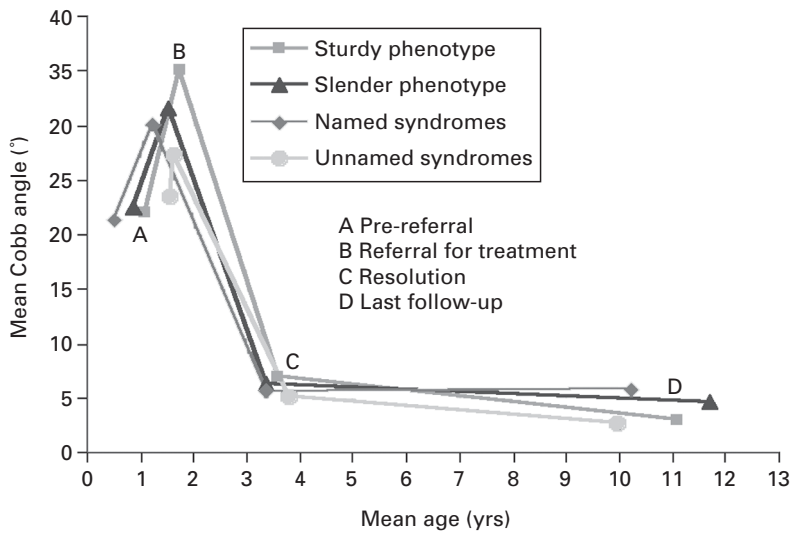


Fig. 5a

Graphs charting the outcome of treatment in each of the four phenotypic sub-groups of progressive scoliosis in group 1 and group 2, respectively.

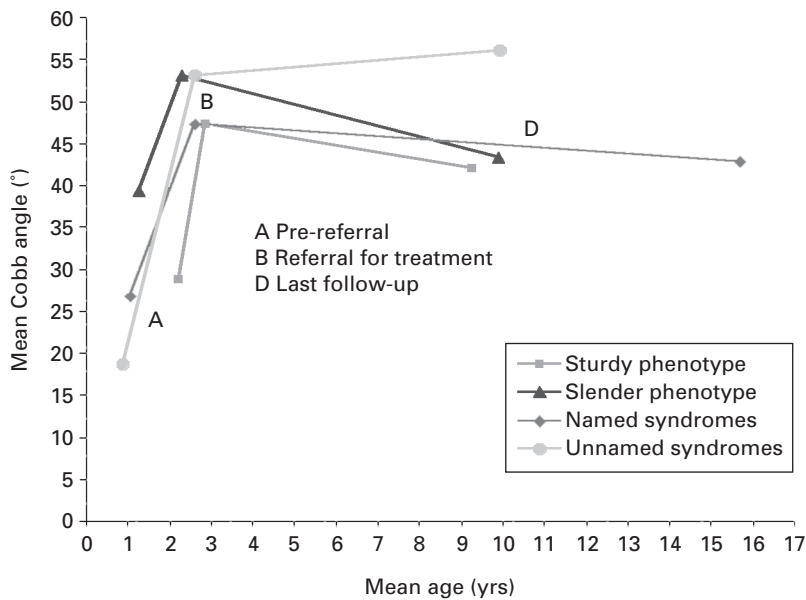


Fig. 5b

Table V shows reduction of the curve and arrest of progression by treatment in the children of group 2. There was no significant change in the radiological variables ($p > 0.1$), apart from a slight improvement in RVAD, during the period of eight years from treatment to the last follow-up. Figure 4 compares the pattern of spontaneous resolution with that of resolution induced by early treatment in group 1, and of failure to resolve by late treatment in group 2.

Figures 5a and 5b shows the results of treatment in each of the four phenotypic categories in group 1 and group 2, respectively. There was no fundamental difference in the clinical composition of the two groups. All four phenotypes were represented in both. Figure 5a shows that all four categories of group 1 responded favourably to treatment and resolved, when the children were treated early between 15 and 21 months with curves measuring 27° to 35° . Figure 5b shows that when the children of group 2 came to treatment aged 27 to 34 months with curves measuring 47° to 53° , none resolved. Only partial correction could be achieved in the first three subgroups and none in the unnamed syndromes. Comparison of Figure 5a with Figure 5b shows a similarity between the Cobb angles at the time of treatment (point B) in group 1 and at pre-referral (point A) in group 2, suggesting that had the children in group 2 been referred for treatment earlier their scoliosis might also have resolved.

Discussion

Progressive infantile scoliosis, idiopathic and syndromic, has a potential for recovery and is reversible, but only when it is treated in the early stages of progression, and preferably during the first two years of vigorous growth. The corrective force in converting a scoliotic spine into a permanently normal spine is the growth of the spine itself, channelled in an increasingly corrected direction and held rigidly by serial, non-removable plaster-of-Paris jackets. However, when treatment is delayed until the deformity is established and the child older, as in group 2, the potential for recovery appears to be lost. The scoliosis can no longer be reversed and becomes permanent.

This study shows that the progressive form of infantile scoliosis occurs in children of different phenotypes with inherently different degrees of vulnerability to deformity and of capacity for recovery by treatment. Whereas the scoliosis in children of the sturdy phenotype will tolerate some delay in treatment and yet be able to resolve, this is not so in those of the slender phenotype or in those with named and unnamed syndromes, who all appear to have a greater susceptibility to deforming forces and a diminished potential for recovery. A short delay of even a few weeks between detection and treatment is sufficient for some syndromic curves to progress to a point where reversal is no longer possible. No exact time for the commencement of treatment can therefore be set by the conventional criteria of age or degree of Cobb angle for all cases. It must be timed individually according to the constitutional make-up

of the child. It is best to follow a confirmed diagnosis of progressive scoliosis with prompt treatment.

Apart from the difference in the period of delay between the detection of scoliosis and the children's referral for treatment (Table I), there appeared to be no other significant factor to account for the disparity in the results of treatment of groups 1 and 2. Avoidance of delay in treatment is of crucial importance. The delays in this study were not because of late detection (Table I). The scoliosis was detected early and mostly by parents, who immediately consulted their family doctor. The children were then promptly referred to paediatric and orthopaedic consultants at the nearest hospital. The delays began at that stage by overlong monitoring for progression of the scoliosis and from investigations for other associated anomalies. A similar pattern of early detection by parents followed by delayed referral by paediatricians and orthopaedic surgeons for specialist treatment, and the deleterious effects of that delay on the magnitude of the scoliosis at treatment, was described by Conner^{19,20} almost 20 years ago.

Delays can also be avoided by undertaking investigations for associated anomalies in parallel with treatment of the scoliosis. In 11 children of the slender phenotype a definitive diagnosis was reached by investigations while they were under treatment and in some cases several years after its completion. Six children in group 1 were found to have motor sensory neuropathy, translocation of the short arm of chromosomes X and 8, autism, dyspraxia, dyscalculia, and pseudocholinesterase deficiency, respectively, and five in group 2 had Asperger's syndrome, autism with congenital cardiac anomalies, central core myopathy, congenital muscular dystrophy, and loculated syrinx, C6 to T8, which was revealed by MRI in an asymptomatic 30-month-old girl with a right thoracic scoliosis and absent abdominal reflexes in all four quadrants²¹ found on routine examination.

Although the children of group 1 were referred and treated relatively early compared with those in group 2, a delay of 12 months between detection and treatment was much too long, and served only to promote further progression (Table III) and prolong the length of treatment. An analysis of the age at treatment and the time taken for the scoliosis to resolve is shown in Table VI. The correlation between the speed of growth and the speed of resolution by treatment supports the conclusion that smaller curves in younger children can be made to resolve in a shorter time, especially when they are treated during the first 12 months of most rapid growth.

If the aim of reversing progressive infantile scoliosis is to be realised, prompt treatment with minimal or no delay should follow a confirmed diagnosis of progressive scoliosis, reached by measuring the RVAD at the apical vertebra and noting the phase on two successive radiographs taken two to three months apart.⁹ This is true for all infants with progressive scoliosis, but especially for children at risk of rapid progression,⁴ such as those of the slender phenotype

Table VI. Correlation of the age at treatment and time to resolution of scoliosis (mths) in the 94 children in group 1

Year children treated in	Number of children	Mean Cobb angle (°)	Time to resolution of scoliosis (mths)
First	32	29	17
Second	40	32	23
Third	17	34	29
Fourth	5	43	45

and those with or suspected of having an underlying syndrome.

In Table II it can be seen that although the mean RVADs in groups 1 and 2, of 28° and 39°, respectively, were well above 20°, a wide range of 0° to 70° in group 1, and 4° to 80° in group 2, would suggest that the children treated with low RVADs may have had spontaneously resolving scoliosis. To address that concern, all cases with a RVAD of < 20° at the commencement of treatment were identified and analysed. Of the 136 children, 29 (21%) had RVAD of < 20°; 26 were in Group 1, and three in Group 2.

In group 1, the mean Cobb angle at treatment of the 26 children was 26.3° (13° to 42°). In 15 children, a pre-referral radiograph was available to show evidence of progression when compared with those taken at referral for treatment. Five children were at an advanced phase 2 stage of progression. The four lowest RVADs were 0°, 5°, 5° and 8°. In the remaining 22 children, the RVAD was between 10° and 19°. The child with the 0° RVAD had an 'idiopathic' curve, detected at five months by her physiotherapist father. A pre-referral radiograph at the age of five months had shown a thoracolumbar curve of 15° with 5° of rotation. At presentation, at the age of eight months, the curve had increased to 23° and rotation to 15°. The two children with 5° RVADs were a 20-month-old spastic and mentally retarded girl with an unnamed syndrome, and a 13-month-old boy of slender phenotype with a thoracic curve of 20° and 15° of rotation, and a lumbar curve of 12° without rotation. His sturdy twin brother had a minor spontaneously resolving scoliosis. The child with an 8° RVAD, was a 10-month-old severely retarded boy whose scoliosis had increased by 8° in four months. Eight children were of the sturdy phenotype with a mean Cobb angle of 26°; nine were of slender phenotype, one of whom was later found to have translocation of chromosomes X and 8; three had named syndromes, namely, Crouzon, pseudocatact secondary to 47XX+marker, and merosin positive muscular dystrophy and six had unnamed syndromes of whom five were mentally retarded, and one had congenital cardiac anomalies.

In group 2, the mean Cobb angle at treatment of the three children with low RVADs of 4°, 5° and 16°, was 44.6° (40° to 50°). The first child was a healthy, asymptomatic four-year-old girl whose scoliosis was detected when she was three and a half years old by her parents, and it was considered to be 'idiopathic'. At referral for treatment, on

routine examination, although the abdominal reflexes were present in all four quadrants, they were less brisk on the side of convexity of the curve, indicating the likely presence of syringomyelia.²¹ A spinal MRI, however, revealed an inoperable spinal cord tumour. The second child, with an RVAD of 5°, had an unnamed syndrome and was severely retarded. The third child with a 16° RVAD, had Prader Willi syndrome. A pre-referral radiograph taken at the age of six months had shown a 20° scoliosis, without rotation. At referral for treatment, at the age of 28 months, the Cobb angle had increased to 50°, with 30° of vertebral rotation.

This analysis illustrates that a percentage of children with progressive scoliosis present with a low RVAD⁹ and that when deciding to treat infants with a scoliosis in the early stages of progression, a number of criteria have been, and should be, taken into consideration. The radiological parameters of RVAD, Cobb angle and rotation are, of course, always considered. But it is equally important to take note of the phenotype, the clinical characteristics of developmental delays, and the presence or absence of other associated anomalies. The prognosis of progressive infantile scoliosis is determined by the inherent constitution of the child and the success or failure to induce resolution of a progressive scoliosis by treatment is determined by timely delivery of treatment, according to each individual child's needs. Syndromic scoliosis does not resolve spontaneously.

Infants and young children adapt amazingly well to plaster jackets even when they contract measles or chickenpox. Those treated under the age of three years have no memory of the event. Plaster-of-Paris is more mouldable than the newer synthetic materials. It flattens the rib hump and restores body shape more efficiently. Minor problems such as superficial friction sores are encountered infrequently and heal readily by easing the plaster over the problem area.

Cotrel and Morel¹⁷ describing the EDF plaster jacket technique, stated that "in young children, it should be feasible not only to prevent further progression but above all to use the child's growth to regress structural vertebral and thoracic deformities". This study has contributed to furthering the aim of reversing progressive scoliosis in infancy by demonstrating that far from being an adverse factor, the vigorous growth of infancy is the principal force in converting a progressive infantile scoliosis into a straight spine by early treatment. This perception of growth working as a corrective force in childhood deformities should alter the aim of the treatment of infantile scoliosis from containment to cure, and realise a future when many more children with progressive deformity may be restored to normal appearance and function. It would also, by preventing the development of severe scoliosis and distortion of the rib cage, further enhance the child's well-being by allowing normal unrestricted multiplication of the pulmonary alveolar system and thereby averting crippling dyspnoea or cardiorespiratory failure in early adult life.⁶ To quote Roaf²² "the purpose of treatment is to restore both normal function and

appearance, but, in general, the greatest disability of a patient with scoliosis is the deformity and disfigurement”.

I acknowledge with thanks the participation of the children and their supportive parents; Dr R. Morris, Senior Lecturer in Medical Statistics and Dr G. Nicholson at the Institute of Orthopaedics for statistical advice and analysis; Dr P. Byers for his constructive criticism; Dr G. Morel from whom I learnt the EDF plaster jacket technique at the Institut Calot, Berck-Plage and my research assistant Alison Hebden for her dedicated help with this work.

No benefits in any form have been received or will be received from a commercial party related directly or indirectly to the subject of this article.

References

1. **James JP.** Two curve patterns in idiopathic structural scoliosis. *J Bone Joint Surg [Br]* 1951;33-B:399-406.
2. **Scott JC, Morgan TH.** The natural history and prognosis of infantile idiopathic scoliosis. *J Bone Joint Surg [Br]* 1955;37-B:400-13.
3. **James JP, Lloyd-Roberts GC, Pilcher MF.** Infantile structural scoliosis. *J Bone Joint Surg [Br]* 1959;41-B:719-35.
4. **Mehta MH.** The natural history of infantile idiopathic scoliosis. In: Zorab PA, ed. *Scoliosis: proceedings of a fifth symposium*. London: Academic Press, 1977:103-22.
5. **Reid L.** Lung growth. In: Zorab PA, ed. *Scoliosis and growth: proceedings of a third symposium*. London: Churchill Livingstone, 1971:117-21.
6. **Branthwaite MA.** Cardiorespiratory consequences of unfused idiopathic scoliosis. *Br J Dis Chest* 1986;80:360-9.
7. **Leatherman KD, Dickson RA.** *The management of spinal deformities*. London: Wright, 1988:428-9.
8. **Mehta MH.** A study of infantile scoliosis. Robert Jones Prize Essay. *British Orthopaedic Association*, 1968.
9. **Mehta MH.** The rib-vertebra angle in the early diagnosis between resolving and progressive infantile scoliosis. *J Bone Joint Surg [Br]* 1972;54-B:230-43.
10. **Mehta MH, Morel G.** The non-operative treatment of infantile idiopathic scoliosis. In: Zorab PA, Siegler D, eds. *Scoliosis*. London: Academic Press, 1980:71-84.
11. **Watson EH, Lowrey GH.** *Growth and development of children*. Fifth ed. Chicago: Year Book Medical Publishers Inc., 1967:86-99.
12. **Thompson DW.** *Growth and form: a new edition*. Cambridge: The University Press, 1942:78-9.
13. **Smith DW.** *Recognizable patterns of human deformation*. Vol 21. Philadelphia: W.B. Saunders Co., 1981:114-17.
14. **Conner AN.** Developmental anomalies and prognosis in infantile idiopathic scoliosis. *J Bone Joint Surg [Br]* 1969;51-B:711-13.
15. **Wynne-Davies R.** Familial (idiopathic) scoliosis: a family survey. *J Bone Joint Surg [Br]* 1968;50-B:24-30.
16. **Connor JM, Conner AN, Connor RAC, et al.** Genetic aspects of early childhood scoliosis. *Am J Med Genet* 1987;27:419-24.
17. **Cotrel Y, Morel G.** The elongation-derotation-flexion technique in the correction of scoliosis. *Rev Chir Orthop Reparatrice Appar Mot* 1964;50:59-75 (in French).
18. **Risser JC.** The iliac apophysis: an invaluable sign in the management of scoliosis. *Clin Orthop* 1958;11:111-19.
19. **Conner AN.** Early onset scoliosis: a call for awareness. *Br Med J (Clin Res Ed)* 1984;289:962-3.
20. **Conner AN.** Scoliosis in the West of Scotland. *Health Bull (Edinb)* 1986;44:91-8.
21. **Zadeh HG, Sakka SA, Powell MP, Mehta MH.** Absent superficial abdominal reflexes in children with scoliosis: an early indicator of syringomyelia. *J Bone Joint Surg [Br]* 1995;77-B:762-7.
22. **Roaf R.** The treatment of progressive scoliosis by unilateral growth-arrest. *J Bone Joint Surg [Br]* 1963;45-B:637-51.