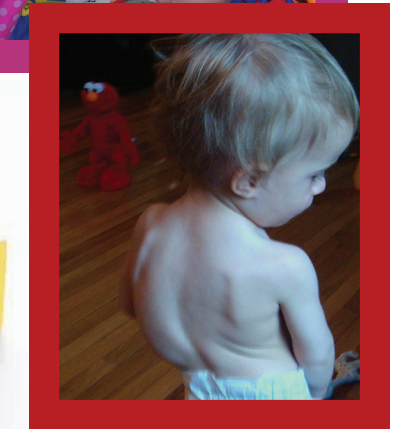
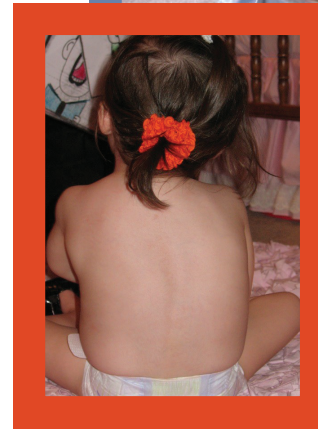






Infantile Scoliosis Tips for Pediatricians and Parents

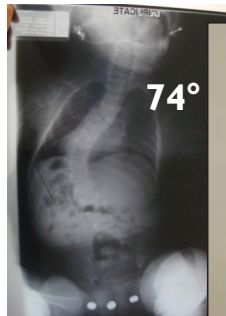
Screening Tips for Infantile Scoliosis (before age 2)

- Begin with the child completely unclothed
- Look for shoulder, hip or cranial asymmetry
- Measure the child's leg lengths looking for unevenness
- Look for generalized ligamentous laxity (loose ligaments)
- Feel the baby self-supporting to rule out floppiness
- Determine whether the skin feels soft and doughy
- Ask parents about the child's motor progress (scooting vs. crawling)
- Ask parents about delayed walking due to balance issues
- Look for a sacral dimple, often just above the crease between the buttocks
- Gently spread the hips apart looking for asymmetry
- When in doubt, obtain a supine AP x-ray of the spine and refer to a pediatric orthopaedic surgeon




Saving Lives with Early Intervention

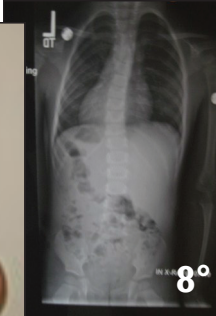In 90% of children diagnosed with infantile scoliosis, the condition will likely resolve on its own. It's for the remaining 10% we must stay vigilant. For this small group, infantile scoliosis can compromise



Before (11 months)



Hadley



After (30 months)

the function of vital organs and threaten young lives. Fortunately, for most kids who are diagnosed early (usually by age 2), a gentle, non-surgical treatment is proving to actually **cure** their curves. The Mehta Method of EDF (Elongation, Derotation, Flexion) treatment provides a series of custom casts that grow with babies, helping children grow straight.

If you suspect a child in your life might have symptoms of infantile scoliosis, please call or write the Infantile Scoliosis Outreach Program (ISOP) right now. We can help you learn more, review options and find a doctor providing early intervention with proper Mehta casting.



Infantile Scoliosis
Outreach Program

www.infantilescoliosis.org
(303) 226-5533 ☼ (866) 417-4873

Get the STRAIGHT Facts for Kids

Simple Screening Methods

Early Detection

Non-Invasive Intervention

Life-saving Treatment



This free screening guide is brought to you by the
Infantile Scoliosis Outreach Program (ISOP)
www.infantilescoliosis.org
(303) 226-5533 ☼ (866) 417-4873

Infantile
Scoliosis
Outreach
Program


Early Detection for Infantile Scoliosis: What to Watch For

Head Tilt or Turn

Torticollis (cervical dystonia or spasmodic torticollis) is a type of movement disorder in which the

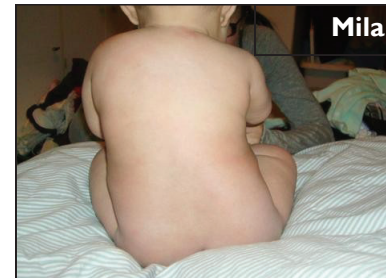muscles controlling the neck cause sustained twisting or frequent jerking. In infants, it often appears as a slight tilt or turn of the head and progresses until the child clearly can not move beyond the tilt or the turn. The child will consistently favor that side, and will eventually stop turning to the other side, a strong sign that a screen for infantile scoliosis should be performed.

Andrew

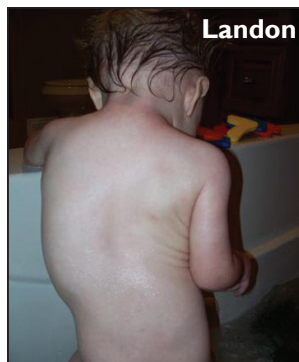

Shoulder & Hip Tilt

Another early indicator of potential scoliosis is an observable tilt to the child's shoulders and/or hips (pelvic tilt). As with many signs, this is best seen when a **diaper is removed**.

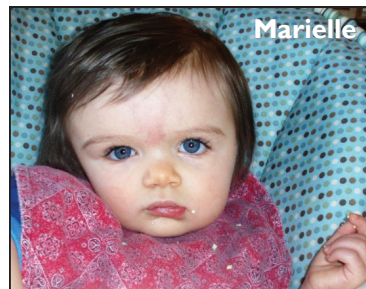

The "hump" in kids' ribs is caused by rotation of the spine. While we can't see the rotation, its effects become obvious over time: one side of the ribs will bulge (convexity), while the other side looks sunken (concavity). On the side of the concavity, we notice telltale creases in the skin. Sometimes convexities appear to be only muscle bulges, a less significant problem, but signs such as these need to be immediate red flags that scoliosis could already be present.



Asymmetrical Cranial Features

Plagiocephaly occurs when the connections between the skull's bony plates (sutures) grow too fast on one side of the head. This can cause mild to moderate changes in facial shape.



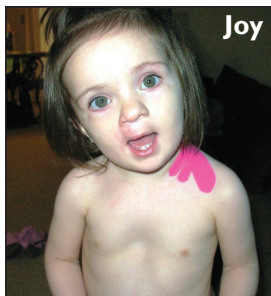Because changes in a face may be difficult to detect day-to-day, photos can help you watch for symptoms. Plagiocephaly is a potential predictor of infantile scoliosis, and a condition that itself needs further assessment.

Rib "Hump" & Waist Creases

Chest Wall Asymmetry

If a child's chest is imbalanced in size or shape, it could need more scrutiny. As it advances, pectus excavatum (when the chest sinks inward) or pectus carinatum (when the chest bulges outward) become more visible. These are clear indicators of a potential problem. Further assessment should be sought immediately.

Joy



What We Can't See

Many key signs can't be seen just by looking, but we still have clues. Subluxation of the hips (having one or both slightly out of socket) can sometimes be detected by clicking sounds made when a baby's legs are splayed. Children who have infantile scoliosis often have an acid reflux disorder; they throw up frequently and must remain upright to feel comfortable. They may also have a harder time than their peers sitting upright without support. Crawling, too, may be difficult. The child may bottom-scoot instead. The first detectors for signs of infantile scoliosis are most often parents. If you feel unevenness, bulges that you don't recognize, see changes over time, trust yourself and ask your pediatrician. The screening exam takes minutes, and the window of opportunity for early intervention closes early. Every child needs at least one thorough screening exam. Talk to your baby's doctor today.